

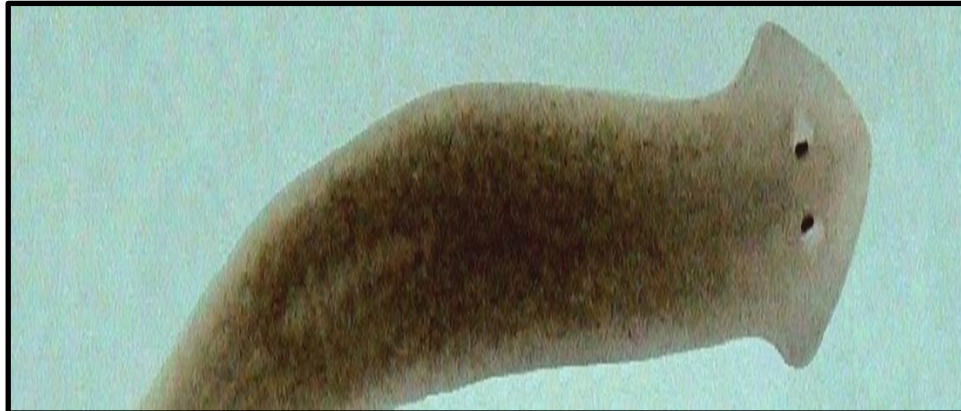

**UNIVERSIDAD AUTÓNOMA DE SAN LUIS POTOSÍ**

**FACULTAD DE CIENCIAS QUÍMICAS**

**Laboratorio de Microbiología**

***Fatal neonatal sepsis caused by vertical transmission of *Morganella morganii*.  
Report of one case***



Student: Citlali Lisset Herrera Rivera  
Teacher: QFB. Juana Tovar Oviedo  
Group: 10:00-11:00

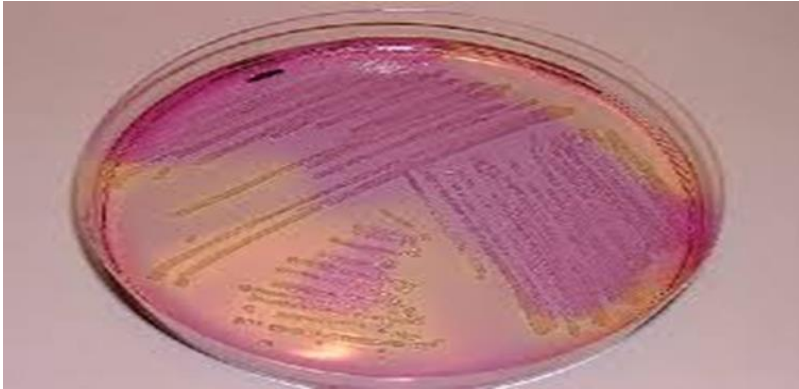- Alfredo Ovalle<sup>1</sup>, M Angélica Martínez<sup>2</sup>, Elena Kakarieka<sup>3</sup>, Mirna García<sup>1</sup>, Abril Salinas<sup>1</sup>

1 Service and Department of Obstetrics, Gynecology and Neonatology, San Borja Arriarán Hospital, Faculty of Medicine, University of Chile, Chile. 2 Microbiology Program, I.C.B.M., Faculty of Medicine, University of Chile, Chile. 3 Service of Pathological Anatomy, Hospital San Borja Arriarán, Chile.

# OBJECTIVE

- Apply the knowledge obtained through the practices performed in the microbiology laboratory to be able to understand a clinical case

# INTRODUCCIÓN



*Morganella  
morganii*, tribus *Proteeae*, familia  
*Enterobacteriaceae*,

Is an opportunistic pathogen that is part of the normal intestinal microbiota of the human being.

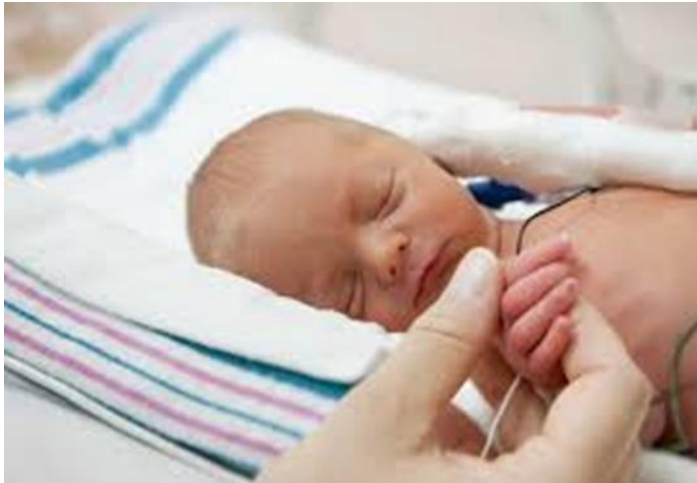

It is a relatively uncommon cause of disease, being isolated mainly in adult infections: urinary, skin, soft tissue, pneumonia and sepsis.



Important predisposing factors: advanced age, prior surgery and debilitating diseases such as diabetes, neoplasms, HIV / AIDS infection.

The majority of the cases described in the literature correspond to severe neonatal infections of early onset, pneumonia and sepsis, with the antecedent of preterm birth and especially with premature rupture of membranes.



## CLINICAL CASE

- Primigesta, 15 years old, with gestation of 40 weeks, who entered the Obstetrics and Gynecology Service of the San Borja Clinic Hospital Arriarán on May 11, 2008, at 05:40 h for presenting labor in the dilation phase (5 cm of dilatation) and expulsion of amniotic fluid (LA) with meconial dye. Had a precocious rupture of membranes 1 h 20 min before admission.


Pregnancy was monitored regularly and was considered as physiological.

At admission, the patient was afebrile, normotensive and pulse rate 80 per min.


In the obstetric examination, 5 cm of dilatation, supported cephalic presentation, ruptured membranes, LA with meconial dye and normal cardiofetal beats (LCF) were found.

Continuous epidural conduction anesthesia and electronic monitoring revealed a variability of less than 5 LCF, an average fetal heart rate of 150 beats per min and a prolonged variable deceleration (up to 120 LCF per minute for 3 min).


The vaginal delivery occurred at 7:24 h on May 11 (1 h 44 min from admission).



We obtained a newborn (RN) of 3-440 g male, with very bad smell, very depressed with Apgar 1 a minute and 3 at 5 min.



The presence of meconium in labor and the aspiration of the secretions of the newborn were not described.



In arterial cord blood, pH 6.9, BE-25 and CO<sub>2</sub> 35 were found. Severe intubation was given to the neonatal ICU, with diagnoses: severe perinatal asphyxia and probable congenital infection.



The RN evolved always severe, with CNS involvement, ischemic hypoxic encephalopathy grade III, associated with early septic shock, with multiorgan compromise and need for ventilatory support and vasoactive drugs.




At 24 h of life the blood cultures taken at birth were positive for *Morganella morganii*

Antibiotic scheme: by **cefotaxime**, according to antibiogram. The tests showed: blood count with leu-copenia, C-reactive protein 129 mg / L, lactic acid 138 mg / dL.

Chest x-ray revealed bilateral parenchymal infiltrate compatible with bronchopneumonia.

The brain scan and ultrasound showed cerebral edema and left posterior fossa hemorrhage concordant with severely altered EEG in convulsive status.

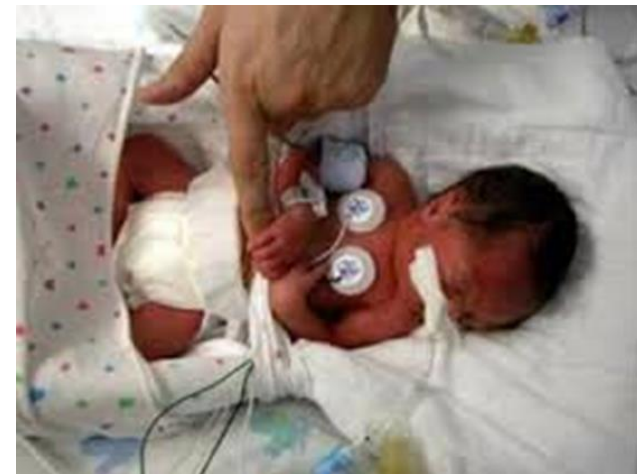## *Morganella morganii*



The neonate died at 17 days of age. The autopsy revealed: term newborn, suitable for gestational age, with morphological signs of septic shock: disseminated intravascular coagulation, hepatic infarction, adrenal glands and splenic congestion. Bilateral scaly and haemorrhagic bronchopneumonia. Cerebral compromise with hypoxic-ischemic encephalopathy.



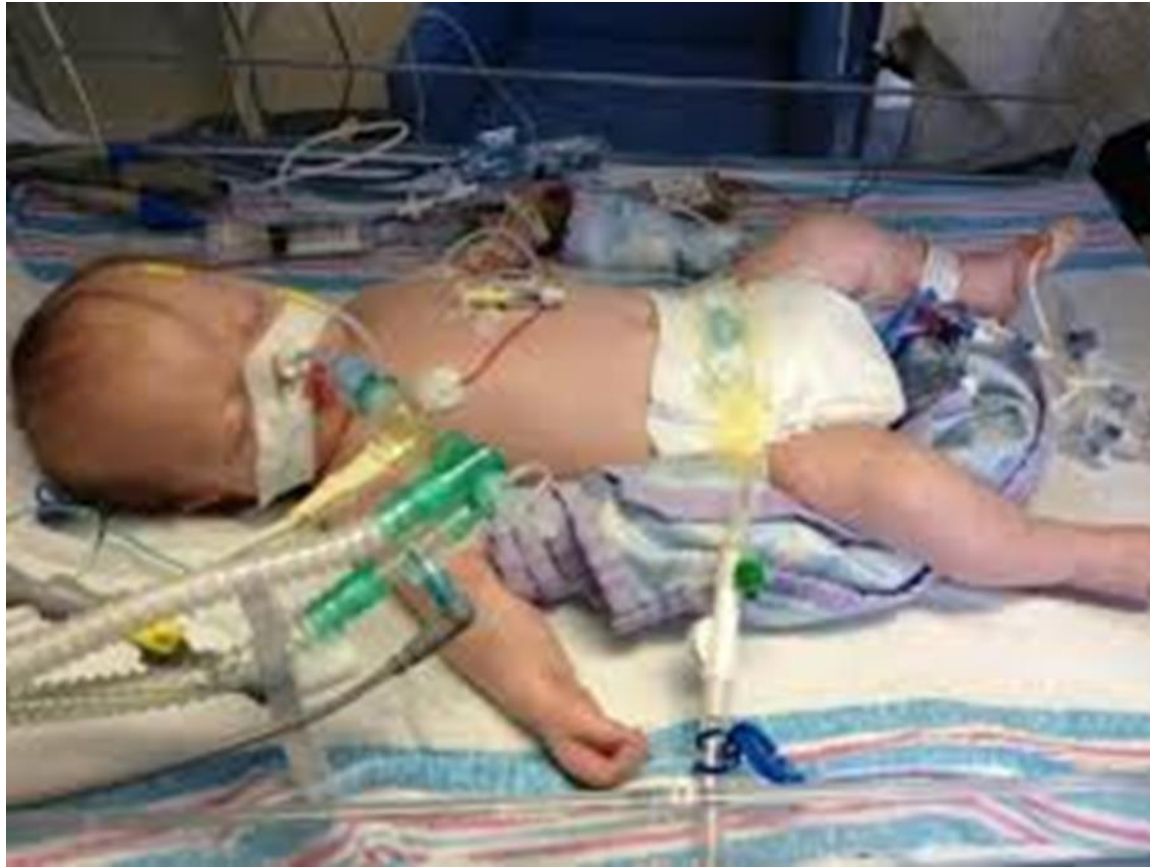Placental biopsy revealed acute abscess  
chorioamnionitis,  
acute funisitis and  
acute focal  
perivillitis



The mother evolved afebrile, without clinical signs of infection, but with culture of lochia positive for *Morganella morganii*, sample taken on the first day of puerperium of the vaginal sac.

She was discharged three days postpartum and treated for 5 days with gentamicin 160 mg IM daily. It was controlled 11 days postpartum in the polyclinic of the Therapeutic Diagnostic Center and was discharged definitively in good physical condition.



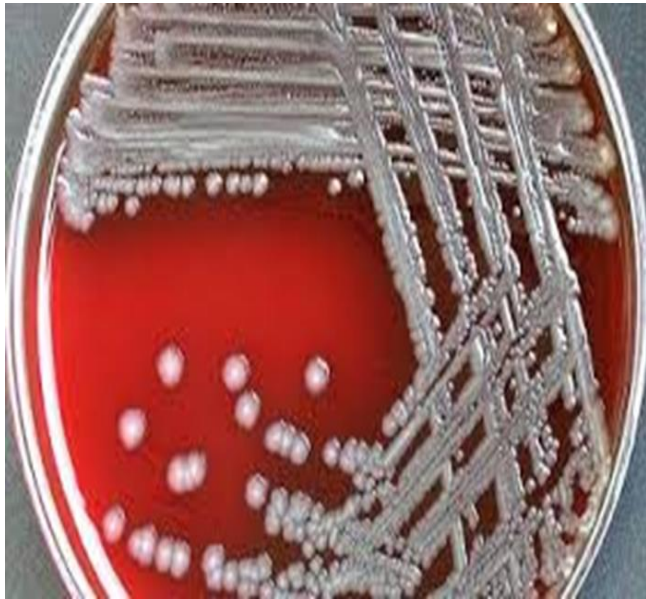

- **CONCLUSION OF THE CLINICAL CASE**

- The clinical case presented corresponds to a congenital sepsis by *M. morganii* and is the first described in a term birth, without premature rupture of membranes and without clinical manifestations of infection in the mother.

The diagnosis of neonatal sepsis by *Morganella morganii* was made early at 24 h of life, by compatible clinical manifestations and by the isolation of the bacterium in the neonate's blood





The initial empiric antibiotic treatment with ampicillin-sulbactam was replaced by cefotaxi-ma upon the isolation of *M. morgani* and its susceptibility to third-generation cephalosporins.

It is important to note that *M. morgani* is intrinsically resistant to first generation cephalosporins, aminopenicillins and other antibiotics such as polymyxin B, nitrofurans and that its resistance to  $\beta$ -lactam antibiotics is mediated by an inducible chromosomal  $\beta$ -lactamase type AmpC group 1 / class C that is not inhibited by sulbactam<sup>1</sup>

The antibiogram of this strain also demonstrated susceptibility to trimethoprim-sulfa-methoxazole, gentamicin, amikacin and ciprofloxacin and resistance to ampicillin and cephalothin.

# BIBLIOGRAPHY

- [http://www.scielo.cl/scielo.php?script=sci\\_arttext&pid=S0034-98872009000900010](http://www.scielo.cl/scielo.php?script=sci_arttext&pid=S0034-98872009000900010)
- O'Hará CM, Brenner FW, Millar JM. Classification, identification, and clinical significance of *Proteus*, *Providencia*, and *MorganeJJa*. *Clin Microbio] Rev* 2000; 13: 534-46. [ Links ]
- 2. Falagas ME, Kawadía PK, Matadakis E, Kofteridis DP, Bliziotis IA, Saloustros E et al. *MorganeJJa morganii* infections in a general tertiary hospital. *Infection* 2006; 34: 315-21. [ Links ]
- 3. Lee I-K, Liu J-W. Clinical characteristics and risk factors for mortality in *MorganeJJa morganii* bacteraemia. *J Microbiol Immunol Infect* 2006; 39: 328-34.